

MicroPure – a New Technology in Clinical Breast Care

S. Anufrieva, A. Blinov, A. Kuznetsov

South Urals State Medical University, the Ministry of Health of the Russian Federation

This article presents data on MicroPure, a modern ultrasound technology used in clinical breast care. The possibilities of the method and the nature of the microcalcifications detected are described. While the diagnostic value of MicroPure technology is comparable to X-ray mammography, the efficiency of targeted biopsy of grouped microcalcifications, a common pre-clinical sign of breast cancer, is improved.

Keywords: breast, ultrasound technology, microcalcifications.

Introduction

Breast cancer is the leading type of cancer in women. For many years, the gold standard of breast cancer diagnosis has been a triple method comprising clinical examination, ultrasound (US)

examination and/or mammography, followed by morphological verification of the diagnosis.¹ The benefits of mammography in the early detection of breast cancer in patients older than 40 years are indisputable due to the ability to visualize non-palpable lesions and clusters of microcalcifications which are frequently the only early manifestation of breast cancer.²

Visualization of microcalcifications by US is limited by the insufficient resolution of the US scanners available in hospitals.³ MicroPure is a modern microcalcification imaging technology in breast US examination implemented in Toshiba Aplio scanners. We evaluated the diagnostic value and possibilities of use for early breast cancer detection of this new technology.

Materials and methods

The study included 52 women aged 18 to 64 (mean age 42.5) with breast pathology: 7 (13.5%) patients with breast cancer and 45 (86.5%) patients with benign breast changes. The patients underwent clinical examination, x-ray mammography, standard breast US examination, biopsy of revealed lesions followed by morphological verification. The protocol of diagnostic evaluation also included a US examination using MicroPure technology.⁴ The MicroPure technology allowed clear visualization of microcalcifications as bright white glowing objects on a dark blue background. In this examination the two sections of the screen reflect the standard B-mode and the region of interest in MicroPure mode.

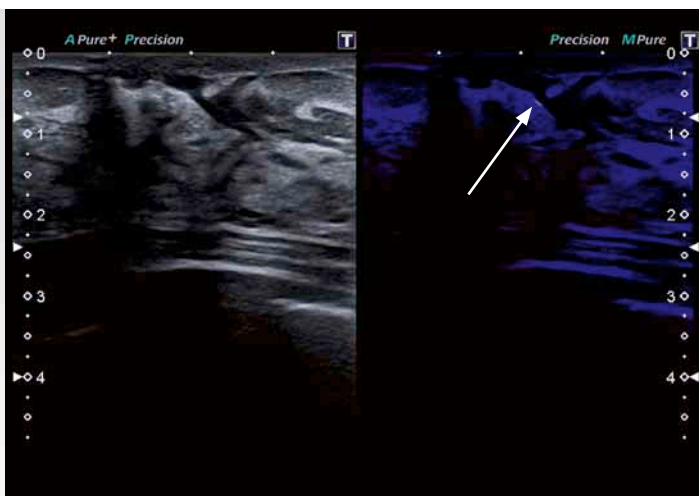


Figure 1: Linear pattern of microcalcification distribution in the postoperative scar in patient K, 29 years, after sectoral breast cancer resection.

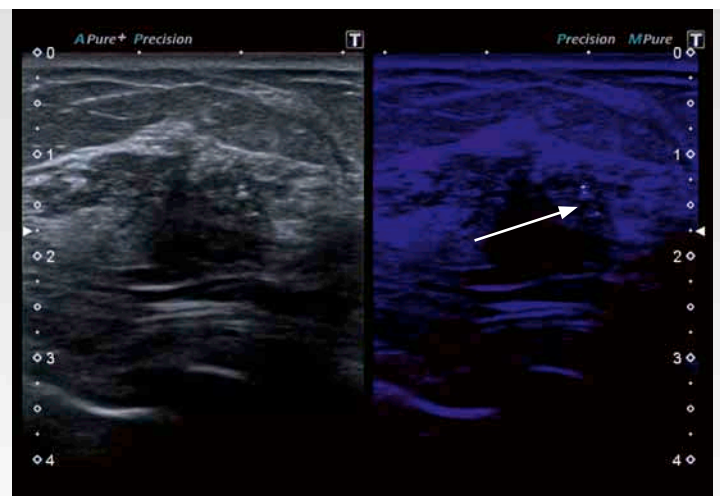


Figure 2: Clustered pattern of microcalcification distribution in the ductal carcinoma in situ in patient G, 42 years old. Scanning in B-mode showed a decrease in tissue echogenicity in the region of interest.

Results and discussion

Breast microcalcifications identified by US MicroPure mode in 18 (34.6%) cases occurred in linear, segmental, and clustered patterns. Distribution of calcification by location in the tissues is presented in Table 1 and Figs. 1 and 2.

Morphological examination of the breast tissue obtained by trepanobiopsy under US control in MicroPure mode revealed the presence of an atypical mammary epithelium. Subsequent study of surgical specimens from patient G, 42, revealed multifocal growth of ductal carcinoma in situ, and genetic study revealed a homozygous BRCA-1 gene mutation carrier state; therefore, subcutaneous mastectomy was performed with implant placement.

A clustered microcalcification pattern was detected in one (5.5%) patient with lactoceles. In this case, multiple microcalcifications filled almost the entire volume of the hypoechoic lesion visualized, and were ballotable.

A segmental microcalcification pattern in MicroPure mode was found in one case. Individual dispersed microcalcifications were located in one glandular breast lobule. Biopsy did not show any proliferative changes in the studied tissues.

Comparison of the MicroPure US data with the results of X-ray mammography showed the same frequency of microcalcification detection in the breast tissues studied. The X-ray mammography was performed in 12 patients older than 40 years. Linear microcalcifications were detected in 11 cases by both methods, US scanning and X-ray mammography. Typically, linear microcalcifications were located along the walls of blood vessels, which was confirmed by both US examination in power Doppler mode and mammography.

Clustered microcalcifications were detected in one patient with breast carcinoma in situ, and only by US in MicroPure mode. Microcalcifications were not visualized by mammography in this case due to the high density of the breast tissue on a background of fibrous dysplasia.

In two cases the MicroPure technology enabled targeted biopsy with precise localization of the biopsy needle in a cluster of microcalcifications. Morphological examination of the material obtained revealed the presence of sclerosing adenosis in one patient, and ductal carcinoma in situ in another patient.

Thus, the first experience of breast ultrasonography with MicroPure technology allowed us to draw the following conclusions:

1. MicroPure technology showed high resolution in the diagnosis of breast microcalcifications, comparable with that of standard X-ray mammography.
2. Targeted biopsy in MicroPure mode is facilitated by the simultaneous realtime visualization of fields of decreased echogenicity and of microcalcifications and improves the efficiency and accuracy of trepanobiopsy.
3. The case of detection of ductal carcinoma in situ using the MicroPure technology indicates the possibility of pre-clinical breast cancer diagnosis but requires further in-depth investigation of the proposed methods of diagnosis.

References

1. Kharchenko VP, Rozhkova NI. Clinical Mammalogy. M. Strom, 2005.
2. Kharchenko VP, Rozhkova NI, eds. Mammalogy: National Handbook. Moscow, GEOTAR-Media, 2009.
3. Alty J, Hoey E, Wolstenhulme S, et al. Practical Ultrasound. Translation from English. Sandrikov VA ed. Moscow: GEOTAR-Media, 2010.
4. Tuhbatullin MG, Aliyeva IM. Modern Ultrasound Technology in Clinical Practice. Practical Medicine. 2012;5:30–35.

The distribution pattern of calcifications	Number of observations, abs./%
Linear	15/83.4%
Segmental	1/5.5%
Clustered	2/11.1%
Total	18/100%

Table 1: Patterns of calcification distribution and the frequency of their detection by US scan in MicroPure mode.

TOSHIBA MEDICAL SYSTEMS CORPORATION

©Toshiba Medical Systems Corporation 2014 all rights reserved.
Design and specifications subject to change without notice.
06/2014 MWPUL0027EUC
Printed in Europe

www.toshiba-medical.eu



ULTRASOUND CT MRI X-RAY SERVICES