

MSK Ultrasound Clinical Case Study

Plantar plate tear



Aaron Fleming
Sonographer
Qscan Red Hill
Queensland, Australia

Graduated with a degree in radiography from Newcastle University in 2009 and completed a post-graduate diploma in Medical Ultrasound at Queensland University of Technology (QUT) in 2013. Aaron has a special interest in MSK ultrasound borne out of a passion for sport.

Introduction

This case follows a 74-year-old female patient who presented with paraesthesia in her right foot and associated pain over the plantar metatarsal area.

Case Study

Ultrasound examination was performed on the Canon Aplio i800 / Prism Edition system using a 24 MHz ultra-high frequency linear matrix transducer (PLI-2004BX). Scanning the area of pain identified a partial thickness tear of the second and third plantar plates. Additional reported findings included pericapsular fibrosis of the second metatarsophalangeal (MTP) joints, a small neuroma in the third webspace, plantar fat oedema and small effusions of the second, third and fourth MTP joints.

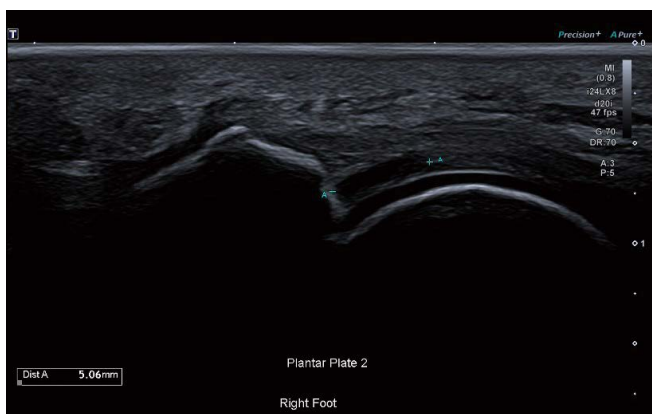


Figure 1 Longitudinal imaging of the second plantar plate shows a 5 mm tear.

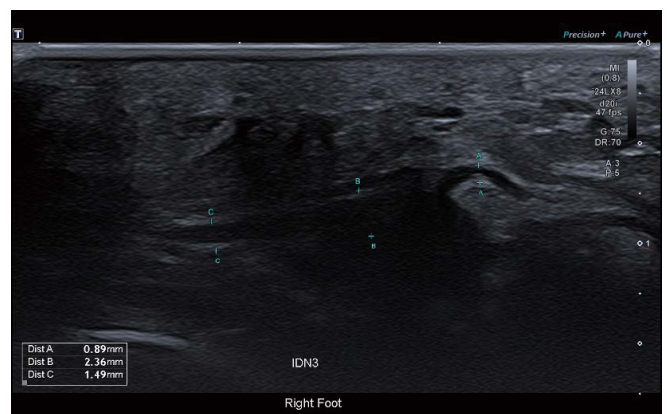

Figure 2 Imaging of the interdigital nerve shows slight thickening of a small section of the nerve. At its narrowest it measures 0.9 mm with focal thickening to 2.4 mm, suggesting possible neuroma.

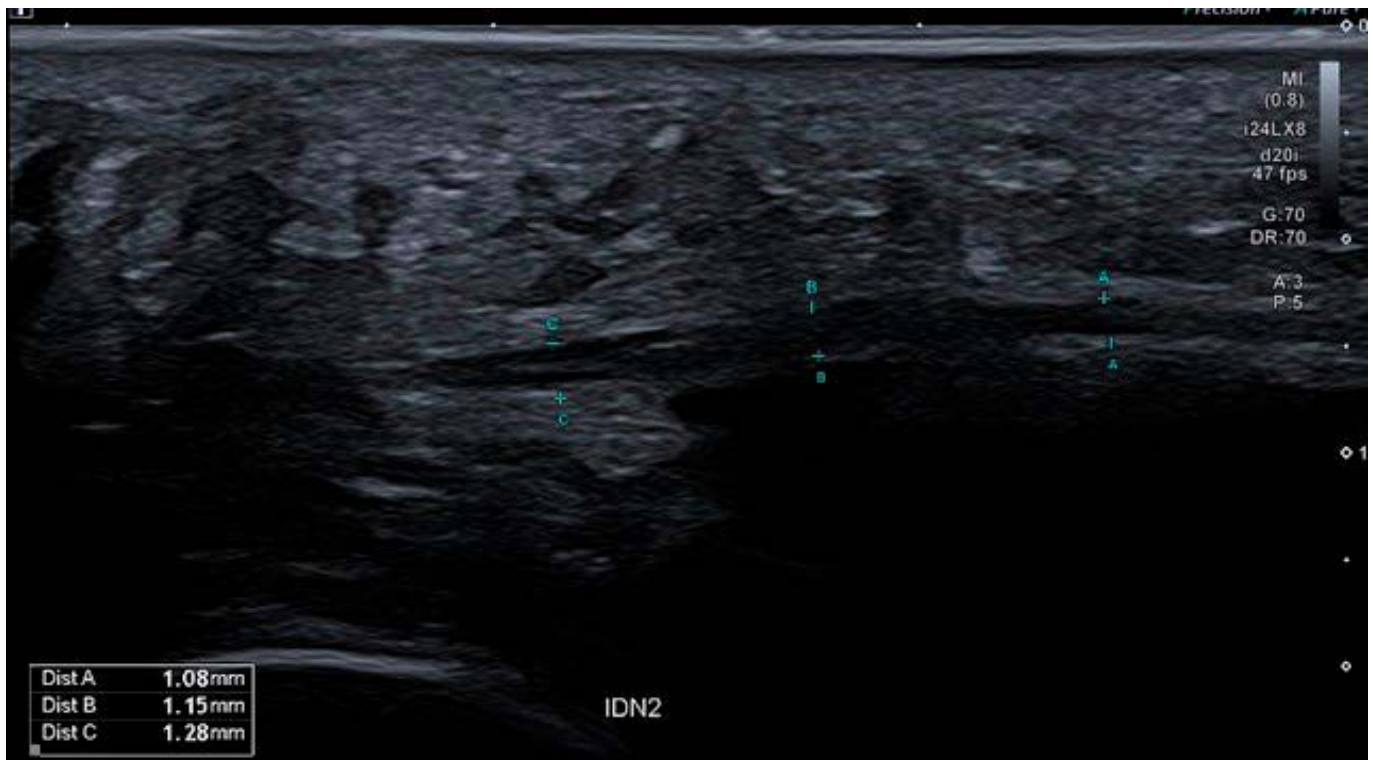

Figure 3 A normal/non-thickened interdigital nerve.

Discussion

High resolution imaging is paramount in MSK imaging. Small nerves and tendons can be difficult to visualize with poor spatial and contrast resolution. The interdigital nerves previously have been difficult to image, requiring fine detail and good penetration. The 24 MHz ultra-high frequency linear matrix transducer makes these small structures easier to visualize and evaluate accurately.

Images in this study were obtained utilizing Canon's iDMS (intelligent Dynamic Micro-Slice) technology, where the Aplio

i800 / Prism Edition produces a very fine ultrasound beam by controlling each individual crystal in the matrix technology. iDMS generates images with greater clarity and allows users to scan without a set focal zone in the system's 'Full Focus' mode.

Canon's new iBeam+ was also employed in this examination. iBeam+ is the combination of advanced beam forming and greater powered signal reception and image processing. In this exam, iBeam+ made a contact point such as the thick skin of the plantar foot easier to penetrate and receive returning echoes, producing high quality diagnostic images of even the small structures of the foot.



iBeam+ is the next level of ultra-fast and precise beam shaping, enhancing image depth and detail with clear, sharp, and distinct images.

Aplio's iBeam+ beamformer technology enables up to 4 times faster* image processing in real time to provide sharper images with better penetration and thus optimal, more robust results for higher clinical confidence.

*compared to the previous versions of Aplio i-series.

CANON MEDICAL SYSTEMS CORPORATION

<https://global.medical.canon>

©Canon Medical Systems Corporation 2021-2022. All rights reserved.
Design and specifications are subject to change without notice.
Model number: TUS-AI800
MCSUS0013EAA 2022-06 CMSC/Produced in Japan

Canon Medical Systems Corporation meets internationally recognized standards for Quality Management System ISO 9001, ISO 13485. Canon Medical Systems Corporation meets the Environmental Management System standard ISO 14001.

Aplio, Aplio i800 PRISM and Made for Life are trademarks of Canon Medical Systems Corporation.

The clinical results described in this paper are the experience of the author.
Results may vary due to clinical setting, patient presentation and other factors.

Made For life